

# PHEOCHROMOCYTOMA IN A DONKEY. REPORT OF CASE

## Feocromocitoma en un asno. Reporte de un caso

**Abelardo Morales-Briceño<sup>1,2</sup>, Antonio Lamprea-Garrido<sup>2</sup>, Aniceto Méndez-Sánchez<sup>1</sup> and José Pérez-Arévalo<sup>1</sup>**

<sup>1</sup>*Departamento de Anatomía y Anatomía Patológica Comparadas, Edificio de Sanidad Animal, Campus de Rabanales Ctra. de Madrid km 396, 14071, Córdoba Universidad de Córdoba, España.*

<sup>2</sup>*Zoosanitarios de la Sierra, Fregenal de la Sierra, Extremadura-Spain. Email: aamorales13@gmail.com*

### ABSTRACT

The aim of this study was to describe a case of a pheochromocytoma observed in a 25-year-old, donkey. A 25-year-old female Andalusian Breed Donkey (Extremadura, Badajoz, Spain) with weight loss syndrome chronic laminitis and recurrent colic for date six month. Hematology and blood biochemistry reveal no significant changes. On necropsy examination no abnormalities were found in the heart, respiratory organs, urogenital organs or intestines. A large approximately spherical mass of tissue 10 to 12 centimeters in diameter composed of a very friable homogeneous tissue surrounded by a thick pseudo-capsule was located at the posterior pole of the left adrenal gland and continuous with it. Histologically, the kidney was normal. The tumor tissue was composed of regularly shaped cells having round or oval nuclei situated centrally or eccentrically in the cell. The nuclear chromatin pattern consisted of an irregular marginal band and central masses. The cytoplasm was eosinophilic and granular. The cellular organization of the tumor consisted of closely apposed pseudotubular arrangements and solid cords surrounded by a delicate stroma. The pseudo-tubular structures contained central blood spaces. In conclusion, it was reported a case of pheochromocytoma observed in a 25-year-old, donkey.

**Key words:** Adrenal; donkey; pheochromocytoma; pathology

### RESUMEN

El objetivo de este estudio fue describir un caso de un feocromocitoma observado en un asno de 25 años (a). Un asno de 25 años de edad, de raza Andaluza (en Extremadura, Badajoz, España), presentó un síndrome de pérdida de peso, laminitis crónica y cólicos recurrentes durante seis meses. La hematología y la bioquímica sanguínea no revelaron cambios significativos. En el examen de necropsia no se encontraron anomalías en el corazón, sistema respiratorio, urogenital o los intestinos. Se observó una gran masa aproximadamente esférica de tejido de 10 a 12 centímetros de diámetro compuesta por un tejido homogéneo muy friable rodeado por una pseudo-cápsula gruesa, la cual se localizó en el polo posterior de la glándula adrenal izquierda. Histológicamente, el riñón se observó normal. El tejido tumoral estaba compuesto de células de forma regular con núcleos redondos u ovales situados central o excéntricamente en la célula. El patrón de cromatina nuclear se observó en una banda marginal irregular y masas centrales. El citoplasma fue eosinófilico y granular. La organización celular del tumor consistía en arreglos pseudotubulares estrechamente cerrados y cuerdas sólidas rodeadas por un delicado estroma. Las estructuras pseudo-tubulares contenían los espacios sanguíneos centrales. En conclusión se reporta un caso de un feocromocitoma observado en un asno de 25 años.

**Palabras clave:** Adrenal; asno; feocromocitoma; patología

## INTRODUCTION

The adrenal glands are paired bodies lying cranial to the kidneys within the retroperitoneal space. The glands consist of two layers; the cortex and medulla. The adrenal cortex is red to light brown in colour and is composed of three zones. These zones all produce hormones derived from cholesterol, which is abundant in the cells. From the outer to inner, the layers are: Zona Glomerulosa: Secretes mineralocorticoids. Zona fasciculata: Secretes glucocorticoids. Zona Reticularis: Secretes sex steroids and androgens. The adrenal glands receive blood supply from the abdominal aorta, renal artery, cranial abdominal artery and caudal phrenic artery. Capillaries from these branches form a capsular and medullary network. There is a central vein, where venous blood pools, before flowing via satellite veins to join the caudal vena cava. The lymphatic network within the adrenal glands drains into the lumbar aortic lymph nodes. The parenchyma of the adrenal medulla is specialised for neurohormonal release, itself being a modified sympathetic ganglion. It is innervated by preganglionic fibres of the splanchnic nerve. The cortical cells are modified postganglionic neurones. The most common hormonal disorders in horses (*Equus caballus*) affect the adrenal glands (Addison's disease and Cushing's disease), thyroid gland (hypothyroidism and goiter), and the pancreas (diabetes mellitus).

Adenomas of the adrenal cortex are seen most frequently in old dogs (*Canis lupus familiaris*) and sporadically in horses, cattle (*Bos taurus*), and sheep (*Ovis aries*) [6,9]. Adrenal carcinomas occur less frequently than adenomas [6,9]. Neoplastic and hyperplastic disorders that affect multiple endocrine tissues in a single individual are well described in humans but less so in domestic animals [8]. Multiple Endocrine Neoplasia (MEN) in humans is a genetically determined syndrome characterized by the appearance of benign or malignant proliferations within two or more endocrine glands [8]. The primary endocrine tumors that are characteristic of MEN arise from cells that share the capacity for amine precursor uptake and decarboxylation. Pheochromocytoma is a rare tumor arising from the chromaffin cells of the adrenal medulla [8]. Pheochromocytomas are the most common in the adrenal medulla of animals although other tumors may develop from the neuroectodermal cells, which differentiate into either secretory elements or sympathetic ganglion cells [9]. Only a few cases of pheochromocytoma have been reported in horses, but it has been well described in dogs, cattle, and humans the adrenal medulla, which are postganglionic neurons of the autonomic nervous system [5,7]. The diagnosis of this type of neoplasms can be confusing clinically, since the paraneoplastic signs can be multiple, in many cases it can be diagnosed by incidental necropsy. Given the low incidence of this type of tumors, it is important to describe the case to be considered within the differential diagnoses in equid adults with recurrent colic and progressive wasting. The histological pattern represents the diagnostic key of this type of tumors with a low incidence of presentation. The aim of this study was to describe a case of a pheochromocytoma observed in a 25-year-old, donkey.

## MATERIAL AND METHODS

### Case history

A 25-year-old female Andalusian Breed Donkey (Extremadura, Badajoz, Spain) with weight loss syndrome, chronic laminitis and recurrent colic for date six months. This donkey was in load and plow work, for more than 15 years, in the last 2 years he found himself in a refuge for donkeys.

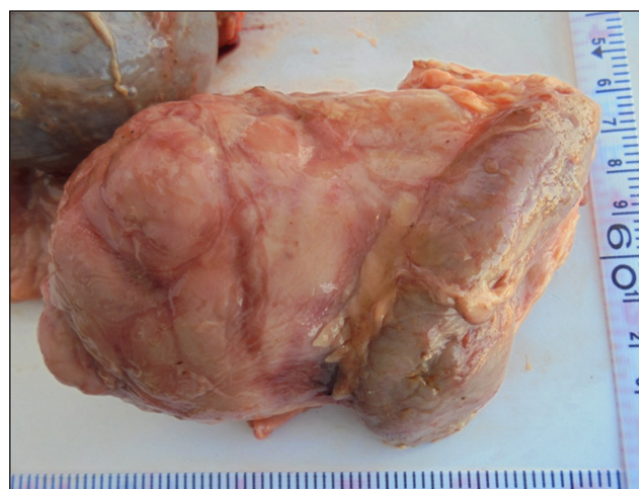### Clinical pathology

Blood samples were collected. Hematology and blood biochemistry revealed no significant changes. Serum phosphorus, and potassium concentrations were within the normal ranges. Serum calcium was 7.1 mmol/L. The blood urea nitrogen and the serum glutamic oxaloacetic transaminase levels (SGOT) were 85 IU/L and 490 IU/L, respectively. The blood glucose concentration was increased to an abnormally high level of 205 mg/100 mL, during last week, the donkey's condition deteriorated and it was euthanized.

## RESULTS AND DISCUSSION

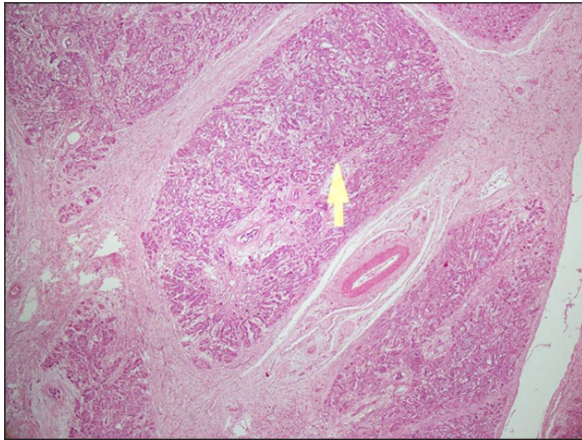
### Post mortem findings

A necropsy was performed immediately after euthanasia. On necropsy examination no abnormalities were found in the heart, respiratory organs, urogenital organs or intestines. A large approximately spherical mass of tissue 10 to 12 centimeters in diameter, composed of a very friable homogeneous tissue surrounded by a thick pseudo-capsule was located at the posterior pole of the left adrenal gland and continuous with it (FIG. 1).

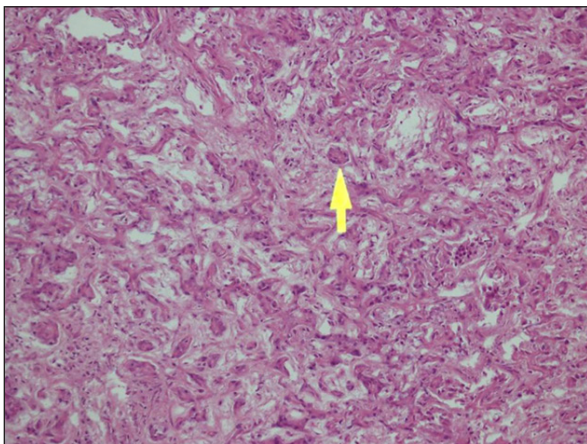


**FIGURE 1. SPHERICAL MASS OF TISSUE 12 TO 14 CM LARGE AND 8CM DIAMETER COMPOSED OF A VERY FRIABLE HOMOGENEOUS TISSUE SURROUNDED BY A THICK PSEUDO-CAPSULE.**

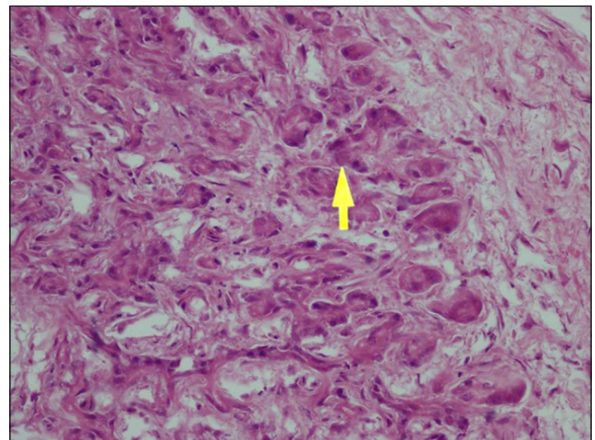
Histologically, the kidney was normal. The tumor tissue was composed of regularly shaped cells having round or oval nuclei situated centrally or eccentrically in the cell (FIGS. 2 and 3). The nuclear chromatin pattern consisted of an irregular marginal band and central masses. The cytoplasm was eosinophilic and granular (FIG. 4). The cellular organization of the tumor consisted of closely apposed pseudotubular arrangements and solid cords surrounded by a delicate stroma. The pseudo-tubular structures contained central blood spaces.



**FIGURE 2. HISTOPATHOLOGY OF ADRENAL GLANDS, STRUCTURE OF TUMOR. NOTE THE PSEUDO-TUBULAR ARRANGEMENT OF CELLS WITH NONEPITHELIAL STRUCTURE. THE ARROW INDICATES THE CELLULAR PATTERN WITH TUMOR CHARACTERISTICS (Hematoxilin& Eosin 4x).**



**FIGURE 3. HISTOPATHOLOGY THE TUMOR TISSUE WAS COMPOSED OF REGULARLY SHAPED CELLS HAVING ROUND OR OVAL NUCLEI SITUATED CENTRALLY OR ECCENTRICALLY IN THE CELL. The nuclear chromatin pattern consisted of an irregular marginal band and central masses. THE CYTOPLASM WAS EOSINOPHILIC AND GRANULAR. THE ARROW INDICATES THE CELLULAR COMPONENT WITH TUMOR CHARACTERISTICS (Hematoxilin& Eosin 20x).**



**FIGURE 4. HISTOPATHOLOGY THE TUMOR TISSUE WAS COMPOSED OF REGULARLY SHAPED CELLS HAVING ROUND OR OVAL NUCLEI SITUATED CENTRALLY OR ECCENTRICALLY IN THE CELL. THE NUCLEAR CHROMATIN PATTERN CONSISTED OF AN IRREGULAR MARGINAL BAND AND CENTRAL MASSES. THE CYTOPLASM WAS EOSINOPHILIC AND GRANULAR. THE ARROW INDICATES THE CELLULAR COMPONENT WITH TUMOR CHARACTERISTICS (Hematoxilin& Eosin 40x).**

A diagnosis of pheochromocytoma was made. Pheochromocytomas are neoplasms arising from the catecholamine-producing, neural crest-derived chromaffin cells of the adrenal medulla, similar neoplasms can also arise from extramedullary chromaffin cells and are referred to as paragangliomas [2]. Previous studies indicate that pheochromocytomas are rare in horses, with a postmortem examination incidence of 1%, and that generally they are clinically silent [5]. Many pheochromocytomas in animals are found as incidental findings at necropsy [9]. In many cases it can go unnoticed or show confusing clinical signs. The ultrasound can play an important role in your diagnosis, mediate the technique of guided biopsy, in this case it was not performed. In a retrospective study in donkeys, any change in adrenal (e.g. adenoma, lymphoplasmacytic infiltration, adrenocortical atrophy, pheochromocytoma, adenocarcinoma or sarcoma) presented a incidence of 8% [8]. They have been detected this neoplasms in foals, mares, pregnant mares and horses with varied clinical presentation. A functional pheochromocytoma was described in a 25-year-old pregnant mare due to foal in nine days [1]. A report of malignant pheochromocytoma in a foal has been describing [4]. A 12-year-old Standard-bred mare and a 21-year-old Quarter Horse gelding were treated for signs of abdominal pain and sweating [4]. Adrenal pheochromocytomas (bilateral in the mare), associated with retroperitoneal and intra-abdominal hemorrhage were found on postmortem examination [5]. Pheochromocytoma was identified in 37/4094 horses during postmortem examination [5]. A recent retrospective study in mature and aged equids describes four cases of pheochromocytoma 3/74 between 15-19 years old and other case 1/25  $\geq$  20 years old [5]. This case

coincides with a donkey marked predisposition from 20 years old in horses. Tumor cells in pheochromocytomas vary from small cuboidal or polyhedral cells, similar to those in normal adrenal medulla, to large pleomorphic cells with multiple hyperchromatic nuclei [8]. The cytoplasmic area is light eosinophilic, finely granular, and often indistinct because of early onset of autolysis in adrenal medullary tissue [3]. These histologic features described matches the tumor reported in this case. Clinical signs consistent with pheochromocytoma had been observed antemortem in only 7 cases, with the remainder being incidental findings [5]. Colic was the most common presenting complaint (13 of 37 cases) and tachycardia was noted in 95% of cases (median heart rate of 86 bp (beats per minute) in clinical cases), concurrent endocrine abnormalities (thyroid adenoma, adrenal hyperplasia, pituitary pars intermedia hyperplasia or adenoma, parathyroid C-cell carcinoma) were found [5]. Recurrent colic in recent months as well as laminitis in this donkey coincides with the clinical presentation of pheochromocytoma in horses. A report of pheochromocytoma concomitant disease with Pituitary Pars Intermedia Dysfunction (PPID), has been reported [6]. Weight loss syndrome, may possibly be considered a paraneoplastic syndrome but unspecific as may occur in other types of tumors. The longevity of this species coincides with the high incidence of tumors, which should always be considered as a differential diagnosis.

## CONCLUSION

It was reported a case of pheochromocytoma observed in a 25-year-old, donkey. This interesting case represents an important diagnostic challenge for the clinician and even for the veterinary pathologist where the necropsy and sampling is key to the diagnosis.

## BIBLIOGRAPHIC REFERENCES

- [1] BUCKINGHAM, J. Case report pheochromocytoma in a mare. **Can. Vet. J.** 11(10): 205-208. 1970.
- [2] CORNER, S; WALSH, T; PADILLA, L; MACNEILL, A; WALLIG, M; KIUPEL, M; TERIO, K. Histologic and Immunohistochemical Characterization of Pheochromocytomas in 20 Clouded Leopards (*Neofelis nebulosa*). **Vet. Pathol.** 54(2): 269-276. 2017.
- [3] FROSCHER, B.G; POWER, H.T. Malignant pheochromocytoma in a foal. **J. Am. Vet. Med. Assoc.** 181(5):494-6. 1982.
- [4] JOHNSON, P.J; GOETZ, T.E; FOREMAN, J.H; ZACHARY, J.F. Pheochromocytoma in two horses. **J. Am. Vet. Med. Assoc.** 206(6):837-41. 1995.
- [5] LUETHY, D; HABECKER, P; MURPHY, B; NOLEN-WALSTON, R. Clinical and Pathological Features of Pheochromocytoma in the Horse: A Multi-Center Retrospective Study of 37 Cases (2007–2014). **J. Vet. Intern. Med.** 30 (1): 309-13. 2015.
- [6] MEUTEN, D.J. Tumors in Domestic Animals. 4th Ed. Iowa State Press, Ames, Iowa, USA, 800 pp. 2002.
- [7] MILLER, M; MOORE, G.E; BERTIN, F.R; KRITCHEVSKY, J.E. What's New in Old Horses? Postmortem Diagnoses in Mature and Aged Equids. **Vet. Pathol.** 53(2): 390-8- 2016.
- [8] MORROW, L; SMITH, K; PIERCY, R; DU TOIT, N; BURDEN, F; OLMOS, G; GREGORY, N; VERHEYE, K. Retrospective Analysis of Post-Mortem Findings in 1,444 Aged Donkeys. **J. Comp. Path.** 144 (2-3): 145-56. 2011.
- [9] MOULTON, J. Tumors of the Endocrine Glands. **Tumors in domestic animals.** 2<sup>nd</sup>. Ed. Los Angeles, California, USA. 2<sup>nd</sup>. Ed. Pp 80-86. 1978.